

A Case Series of Temporomandibular Disorders Treated with Acupuncture, Occlusal Splint and Point Injection Therapy

Yiu-kai Wong, Jason Cheng

Yiu-kai Wong
senior dental officer

Jason Chi-fung Cheng
consultant
Oral-Maxillofacial
Surgery and Dental Unit,
Pamela Youde Nethersole
Eastern Hospital,
Hong Kong

Correspondence:
Yiu-kai Wong

wykj@graduate.hku.hk

Summary

A treatment regime combining acupuncture, occlusal splint and point injection therapy for temporomandibular disorders (TMD) is presented. There were 89 consecutive patients treated by the regime in this case series but four patients dropped out after two to three visits. Data and treatment results of the remaining 85 patients who had treatment completed were analysed. It was found that 73 (85%) of patients with TMD had symptoms relieved within six visits under this regime. Complications were rare and minor. Acupuncture treatment, in combination with splint therapy and point injection therapy, appears to be effective for managing TMD. However, further research, using randomised controlled trials should be conducted to ascertain its effectiveness over other treatment modalities.

Keywords

Acupuncture, temporomandibular disorders, occlusal splint, tender points, point injection therapy.

Introduction

Temporomandibular disorder (TMD) is a non-specific diagnosis that represents a group of painful conditions affecting the temporomandibular joint (TMJ) and the muscles that control chewing. It is a condition that is commonly referred to oral and maxillofacial surgery units for management. Patients frequently present with pain in the face or TMJ area, pain during chewing and wide opening of the mouth, headaches, earaches, dizziness, limitation in mouth opening, clicking or locking of the joint, and other complaints such as neck or upper back pain. Gray et al classified TMD into three major conditions based on frequency of presentation of symptoms as follows:¹

1. Pain dysfunction syndrome (PDS), which is defined as a combination of at least two of the following symptoms: a) pain on palpation of the TMJ; b) pain on palpation of associated masticatory muscles; c) limitation or deviation of mandibular movement; d) joint sounds and headache.
2. Osteoarthritis, which includes joint sounds, limitation of the jaw movement and pain located in the pre-auricular region.
3. Internal derangement, which is characterised by a displacement of the articular disc with

or without reduction, and gives signs and symptoms including clicking of the joints and, at a later stage, pain located at the TMJ.

Acupuncture has been shown to be effective in management of TMD.²⁻⁶ In 2002, the World Health Organisation (WHO) concluded that chronic facial pain, including craniomandibular disorders of muscular origin, responds well to acupuncture treatment. The effect of acupuncture is comparable with that of conventional occlusal, physical and drug therapies for TMD. Acupuncture may be useful as a complementary therapy for this condition.⁷ In the following report we describe a case series of 89 patients diagnosed clinically to have TMD who have been treated with a regime including acupuncture, occlusal splint and point injection therapy.

Methods

Patients referred to the oral-maxillofacial surgery service for TMJ pain were seen by the first author who was also trained in acupuncture. Eighty-nine consecutive patients between March 2001 and December 2002 were treated, but four of them dropped out after two to three visits. The reason for their discontinuation of treatment was unknown, as they did not reattend. Eighty-five

patients completed the whole course of treatment. The first 27 patients of this group received manual needling to local points (the manual group), and the next 58 patients received electroacupuncture (EA) to local points (the EA group), since the acupuncture stimulator was then available.

The methods of assessment and treatment are presented below. Following a pain history, physical examination included recording the maximum incisal opening (MIO), and noting clicking or joint noises. TMJ, neck and upper back areas were palpated for tender points (TePs). Tender points, in this study, are defined as points exhibiting tenderness on palpation. Very often, these points coincide with traditional acupoints and some exhibit the characteristics of myofascial trigger points (MTrPs).^{8,9} MTrPs are hyperirritable spots in a taut band of skeletal muscle. They are painful on compression and can produce referred pain, referred tenderness, motor dysfunction, and autonomic phenomena. When firm pressure is applied over the trigger point in a snapping fashion perpendicular to the orientation of the muscle fibres, a 'local twitch response' is often elicited. TePs, by comparison, are associated with pain at the site of palpation only, not with referred pain, and may occur in muscle, muscle-tendon junction, bursa, or fat pad. The findings were recorded for reference and further monitoring (figure 1).

A panoramic radiograph (OPG) was taken in every patient. Patients with evidence of bone pathology of the TMJ (e.g. rheumatoid arthritis,

osteoarthritis, and idiopathic condylar resorption) or those who had been diagnosed clinically as hybrid cases of TMD and trigeminal neuralgia were excluded from this series.

The nature of the disease TMD was then explained. An upper impression was taken to fabricate an occlusal splint made up of soft mouthguard material (ethylene-vinyl-acetate) with a thickness of 3mm (figure 2). The splint was issued to the patient one week later with instruction for it to be worn during sleep.

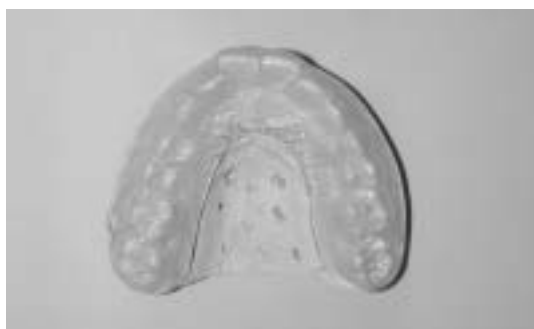

Figure 2 Soft occlusal splint for wearing during sleep.

Acupuncture treatment was started at the first visit. The patient was seated comfortably upright in the dental chair. The skin surface was prepared with alcohol swabs. Local points (TePs in TMJ, neck or upper back) were needled first (figure 3). Disposable filiform needles (0.3mm x 25mm) were inserted at relevant points until 'de qi' sensation (soreness, numbness, distension or heaviness) was achieved. Various distal points

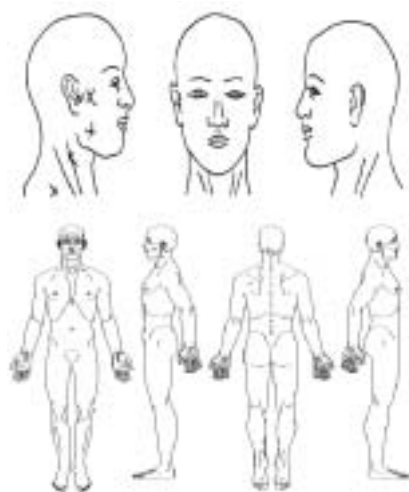


Figure 1 Records for tender points (TePs).

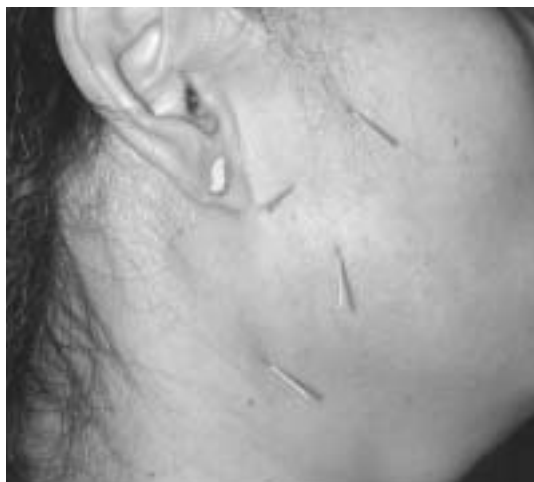

Figure 3 Needles in local points ST7, Qian Zheng, ST6, and SI17.

were used in an attempt to improve the effectiveness of treatment, as is common practice in Traditional Chinese Acupuncture (TCA). Distal points were also used in previous studies on TMD by Raustia et al, Johansson et al and List et al.²⁴ It has been suggested that needling distal points can modulate the sympathetic nervous system and the various 'pain gates', and thus potentially augment the therapeutic effects of needling local points. Distal points routinely used were LI4 on the contralateral side and TE5 on the affected side. For bilateral TMD cases, local points were needed on both sides while LI4 was needed contralateral to the worst side and TE5 was needed on the worst side. In cases where there were prominent psychological components (stress, anxiety or depression), LR3 was added on both sides. ST36 on both sides was also added to older patients who complained of weakness, lassitude and tiredness.

The choice of distal points has embodied some TCA concepts. In TCA, pain is interpreted as stagnation of qi and blood in the meridians, and the goal of acupuncture treatment is to remove obstruction and reverse stagnation. All the yang meridians traverse the head and facial region, and points in the related yang meridians are somewhat inter-changeable, e.g. TE5 (hand *ShaoYang*) and GB43 (foot *ShaoYang*) can be used to treat temporal headaches. The TMJ area is associated with ST (foot *YangMing*), TE (hand *ShaoYang*), SI (hand *TaiYang*), and GB (foot *ShaoYang*) meridians. LI4 contralateral to the affected side is used because the two LI meridians cross the midline at the philtrum, GV26. For example, the left meridian will go to the right side of the nose at LI20, where qi flow is linked to the ST meridian of the right side. In TCA, LI4 is thought to be the single most important point to treat disorders of the face and sense organs, and to produce acupuncture analgesia. TE5, one of the eight confluent points, has the action to expel external wind, harmonise the *ShaoYang* and open the Yang linking vessel, which is connected with all the yang meridians and dominates the exterior of the whole body. It is useful to treat headache, stiffness and pain in the neck and shoulders. In this study, the combination of one hand *YangMing* point (LI4) and one hand *ShaoYang* point (TE5) were

used as distal points in all patients. The use of these two points can regulate qi and blood in *YangMing* and *ShaoYang* areas in the vicinity of the TMJ and temporal areas. The use of LI4 on the contralateral side can also help to balance left and right. According to TCA, those patients who get depression, stress or anxiety always have a component of liver qi stagnation. Sometimes, liver yang rising may present as headache. LR3, the shu-stream and yuan-source point of the liver (foot *JueYin*) meridian, has the action of promoting free flow of liver qi, and subdues liver yang. Combining LI4 and LR3 will open the 'four gates', and will regulate qi and blood, thus reducing pain and spasm in painful obstruction syndromes.¹⁰ In fact, some western medical acupuncturists regard LR3 as having a generalised action that can be used to treat disorders like solar dermatitis, urticaria, bronchial asthma, many gynaecological problems, headache and migraine.^{11:12} ST36 has been well known for its tonification action on qi and blood, and it has been suggested that it has a strong stimulating effect on the immune system. This point is added to patients who complain of weakness, tiredness and lassitude, which are manifestations of qi and blood deficiency.

Manipulation of the needles inserted in local points around the TMJ, neck or upper back was performed every 10 minutes using the reducing method (rapid anticlockwise rotation with 180° amplitude for five turns) where there was no electrical stimulation, i.e. for the first 27 patients. According to TCA, the principle of needle manipulation is to reinforce deficiency and reduce excess. Local tenderness or pain is often caused by stagnation of qi, i.e. 'excess' in nature. The reducing method of needle manipulation has the function of removing qi stagnation so that qi can freely flow in the meridians, and pain will be abolished. TMD, in TCA, can be classified as a type of painful obstruction syndrome, which is 'excess' in nature, in the TMJ and associated area. Therefore, needle manipulation should always be reducing.

Fifty-eight patients received EA to local points (figure 4). The machine used was Model G6805-2 made in Shanghai, China. This is the most common model used in acupuncture clinics in China. A continuous wave form at 40Hz seemed

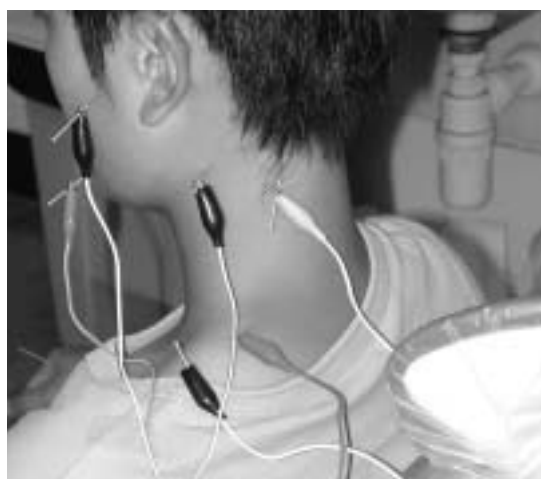

Figure 4 Electroacupuncture (EA) applied to local points in TMJ, neck and upper back.

to be most acceptable to patients after trials on a few patients, and this was arbitrarily chosen as the waveform used. The stimulus intensity was adjusted from zero until there was slight muscle twitching but no discomfort experienced by the patient.

The needles in distal points were manipulated every 10 minutes: reducing method for LI4 and TE5; reinforcing (slow clockwise rotation with 90° amplitude for five turns) for ST36, and reducing for LR3. All needles were retained for 30 minutes. Advice for patients after discharge included avoiding hard foods and applying a hot pack to tender areas. Analgesics were not normally prescribed because most patients had been previously unsuccessfully treated with NSAIDs. Tilcotil (tenoxicam) - one tablet daily for one week only - would be prescribed if the patient requested analgesics. No more analgesics were used afterwards.

Treatment was conducted on a weekly basis. During each visit, the patient was asked for their subjective assessment of pain, whether it had greatly improved, improved, not changed or deteriorated. MIO was also recorded. TePs were again palpated, recorded and treated accordingly. Very often, the number of local points used would be reduced as treatment progressed, but new tender points were occasionally detected.

Point injection was only performed for residual TePs still present after seven sessions. TePs would be needled in the same way as above, but at the end of the acupuncture treatment 0.1ml Kenacort A (triamcinolone acetonide 10mg/ml) and 0.1ml

Table 1 Demographics of case series of 85 patients.

	Number (% of total)
Sex	
Female	67 (79)
Male	18 (21)
Age	
<21	4 (5)
21-40	38 (45)
41-60	35 (41)
>60	8 (9)
Aetiology	
History of trauma	12 (14)
Stress, anxiety, depression associated	9 (11)
No precipitating factors recalled	64 (75)
Duration of discomfort	
<1 month	14 (17)
1-3 months	24 (28)
>3 months	47 (55)
TMJ Pain	
Unilateral	74 (87)
Bilateral	11 (13)
Symptoms (other than joint pain)	
Maximum incisal opening <30 mm	12 (14)
Clicking/joint noise	18 (21)
Neck/upper back pain	27 (32)
Previous treatment	
NSAIDs	74 (87)
Splint therapy	3 (4)
No treatment	10 (12)
Tricyclic antidepressants or Valium	7 (8)

Xylestesin A (2% lidocaine with 1:80,000 adrenaline) mixture was injected into each residual tender point. The patient returned for review one week later. Any residual TePs were treated in the same manner. However, no point was injected on more than two occasions.

Treatment was considered complete when the following two criteria had been achieved: (1) the patient reported being free from pain, and (2) there were no TePs in the TMJ area. An additional acupuncture treatment was given at the last visit. The number of visits needed to achieve the 'pain-free' state was considered to be the total number of visits, minus the last visit. The patient would then be discharged, advised to wear the splint for another month, and to come back for treatment immediately if there was any recurrence of symptoms.

Results

Patient Data

Data from 85 patients whose treatment was completed between March 2001 and December 2002 were included. The demographic details of these patients are listed in table 1. The data

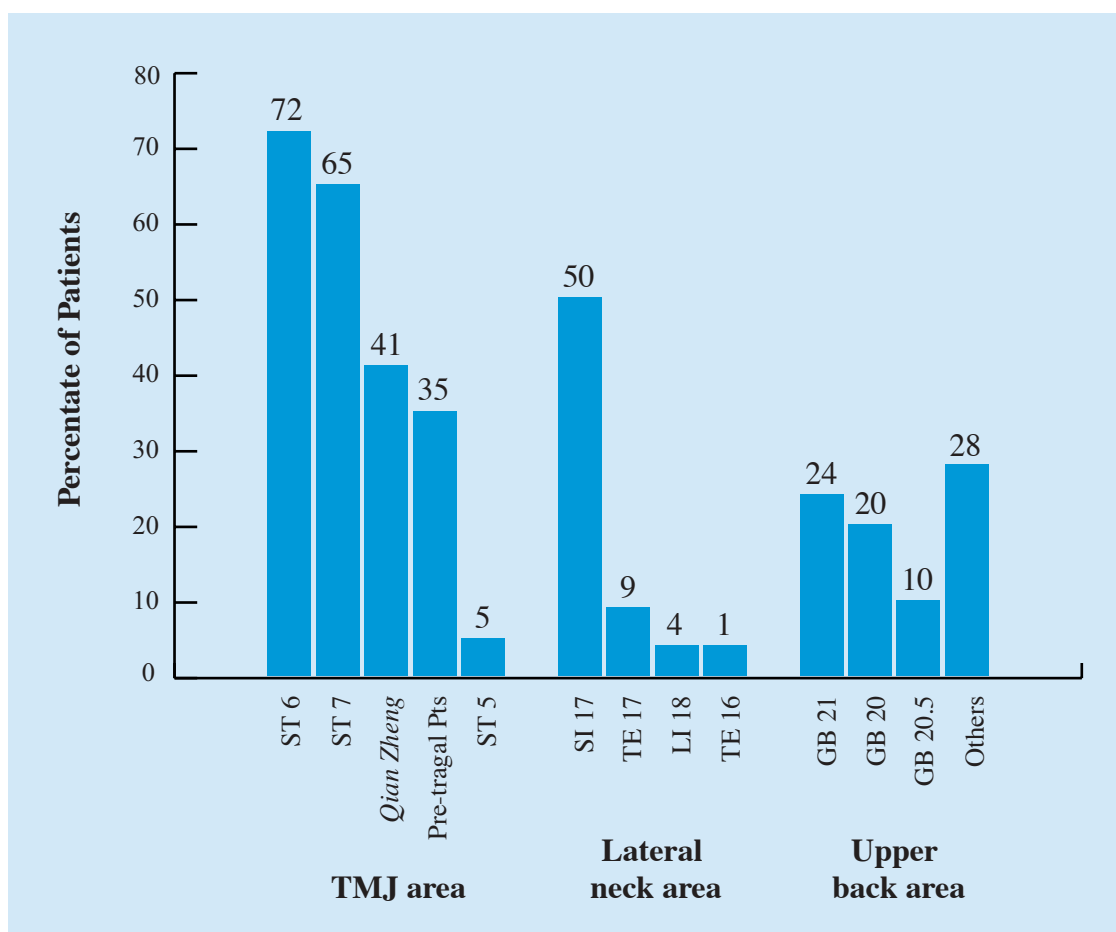


Figure 5 Frequency of TePs at traditional acupoints examined.

relating to four patients who discontinued treatment after two to three visits were excluded from the analysis. All four patients were female: one belonged to the manual group while the remaining three belonged to the EA group.

Tender Points and Traditional Acupoints

The frequency of TePs at the traditional acupoints examined is shown in figure 5. In the TMJ area, the incidence of tender points among patients was, in descending order, ST6 (72%), ST7 (65%), and *Qian Zheng* (41%). *Qian Zheng* is an extra point located 0.5 cun in front of the anterior border of the ear lobe and level with its mid-point. At least one of the pre-tragal points (TE21, SI19, GB2) was tender in 35% of patients. In the lateral neck area, 50% of patients experienced tenderness at SI17. For patients with concurrent upper back pain, various tender points were found in the trapezius (GB20, GB21, GB20.5 {midway between GB20 and GB21}, BL10), and in the

Table 2 Results.

	Number (% of total)
Use of one week tenoxicam	
Tenoxicam prescribed	13 (15)
No tenoxicam prescribed	72 (85)
Subjective response after first treatment	
Greatly improved	44 (51)
Improved	28 (33)
No change	10 (12)
Deteriorated	3 (4)
Free from pain after six visits	
Manual group (27 in total)	23 (85)
EA group (58 in total)	50 (85)
Additional distal points used	
LR3	10 (12)
ST36	7 (8)
Incidences of points requiring injection therapy	
SI19	4 (5)
<i>Qian Zheng</i>	4 (5)
ST6	1 (1)
Incidences of adverse effects among 370 sessions	
Fainting	3(0.8)
Echymosis	15 (4)
Recurrence of symptoms after nine to 12 months	4 (5)

other muscles associated with the scapula (e.g. SI15, SI14, SI11, SI9, etc.).

Treatment results (table 2)

a) Subjective response after initial treatment

Only 13 patients (15%) received a one-week course of tenoxicam. When patients came back one week later for review and were asked about pain and discomfort associated with the TMJ and other areas, 72 patients (84%) reported improvement and a decrease of pain, 10 (12%) reported no improvement, while only three (4%) reported deterioration.

b) Number of visits needed to achieve a 'pain-free' state

All patients could achieve normal mouth opening (MIO>40 mm), and became free of TePs around the TMJ area, on completion of treatment. However, there was little improvement in joint noises. The number of visits needed to achieve the 'pain-free' state was recorded as the total number of visits minus the last visit. Eighty five per cent of patients in each group were rendered free from pain after six visits (23 out of 27 for the manual group and 50 out of 58 for the EA group) (figure

6). The disappearance of TePs around the TMJ area is likely to be due to the effect of acupuncture treatment alone. Two patients in the EA group had residual tender points not completely abolished after seven sessions of acupuncture, but they refused to have point injection therapy. However, the residual tender points resolved after five more visits (i.e. 12 visits in total). The total number of treatment sessions used for all patients was 370.

c) Additional distal points and points that required injection therapy

In addition to LI4 and TE5, 10 (12%) of patients received bilateral LR3 and five (8%) received bilateral ST36. Points that remained tender to palpation after seven visits were subjected to injection therapy after the usual needling. The incidence of relevant points in this group was: SI19 (four patients), *Qian Zheng* (four patients) and ST6 (one patient). However, no patient required injections more than twice for each point.

Adverse Effects

Adverse effects were rare and relatively minor. Three episodes of fainting in three female patients were encountered (two after needle insertion at

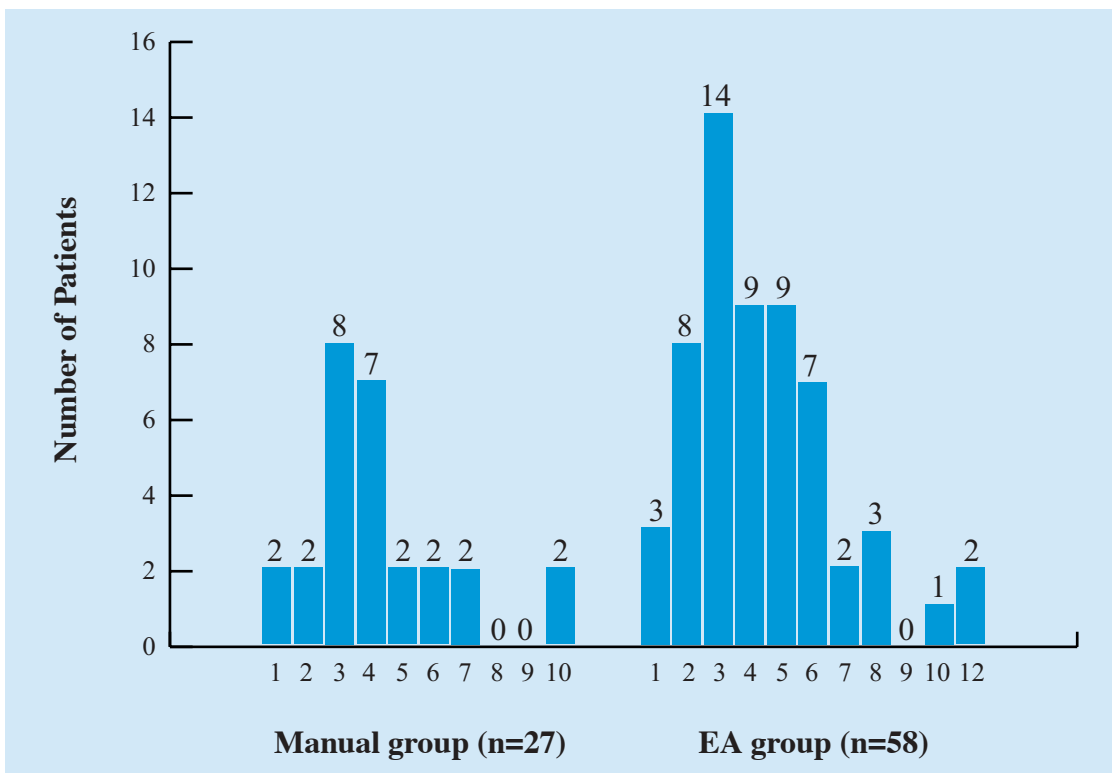


Figure 6 Number of visits needed to achieve pain-free state.

LI4 and one after needle insertion at TE5) out of the total 370 treatment sessions. All the 'needle fainting' happened within 30 seconds of needle insertion but none of the patients developed complete loss of consciousness. The incidence of fainting was 0.8%. All the patients recovered uneventfully soon after the needles were removed and they were laid supine on the dental chair. Ten patients developed bruising associated with needling some points. The relevant points were LI4 (seven times), ST7 (three times), *Qian Zheng* (two times), ST6 (three times).

Recurrence

Four patients (5%) returned for re-treatment because of recurrence of symptoms within nine to 12 months. However, they were rendered pain free again by a further two to four treatment sessions.

Discussion

In this case series, patients were considered to belong to the category of PDS based on a clinical diagnosis. There were no patients in this series who presented with clicking or joint noises alone, without tenderness around the TMJ and the associated masticatory muscles. Moreover, displacement of the articular disc, which is the characteristic of internal derangement, should be confirmed by magnetic resonance imaging (MRI). Patients with evidence of bone pathology of TMJ (e.g. osteoarthritis, osteoarthrosis) shown in OPG were excluded from the study. More females were treated than males, a finding similar to that reported by Gray et al.¹ Surprisingly, a history of stress, anxiety or depression could only be elicited in 11% of patients. This is likely to be under-reported in a city like Hong Kong. Perhaps because of cultural differences, Chinese patients are less open to share their stresses compared with a western population.

There are limitations with respect to the outcome measures used in this series. Patients were asked at each visit whether there had been any subjective change in their pain, and this was rated as greatly improved, improved, no change or deteriorated. This verbal subjective assessment of benefit by the patient may not be as reliable as a visual analogue score (VAS). However, there were other more objective measures to assess

outcomes. First, MIO was recorded for those who initially presented with a decrease in mouth openings. All patients in this series achieved normal mouth opening (MIO > 40 mm) by the end of the treatment. Second, TePs were palpated and recorded at each visit by the same clinician. Improvement was assessed by a decrease in tenderness or disappearance of TePs. Treatment was considered complete when there were no TePs palpable in the TMJ area. The recurrence rate (5%) may be underestimated. First, some patients with recurrence of symptoms might not come back again for treatment. Second, there has been no system of recall or phone contact to make sure that every patient is still symptom-free after a period of time.

It has been suggested that in articular disc displacement disorders, i.e. internal derangement, the articular disc is displaced anteromedially owing to hyperactivity of the lateral pterygoid muscle, resulting in misalignment of the disc and mandibular condyle. In the case of anterior disc displacement with reduction, clicking is produced when the condyle moves forward over the posterior band of the disc on mouth opening and eventually returns to the normal condyle-disc relationship, resting on the thin intermediate zone of the disc. During closing, the condyle then slips posteriorly and rests on the retrodiscal tissue, with the disc returning to the displaced position. In the case of disc displacement without reduction, no clicking will occur because the condyle is unable to translate over the posterior aspect of the disc. However, joint noise such as crepitus can still occur. This lack of translation results in restricted opening and in deviation of the mandible to the affected side. Lateral excursions to the contralateral side are also limited. In both situations, plain X-rays may appear normal and MRI should be used to confirm the anterior displacement of the disc. Many studies indicate that non-surgical treatment can eliminate signs and symptoms in patients with TMD.¹³⁻¹⁵ De Leeuw et al,^{14;15} following a 30-year follow-up study on 99 patients with either reducing or permanent disc displacement treated non-surgically, reported that the disease followed a benign course, with long-lasting and satisfactory results from a non-surgical approach that was well-accepted by the patients.

Chewing ability of the patients did not differ from that of the 35 control subjects, although patients more often expected pain and difficulty with opening the mouth wide. Clicking and crepitus were the most common remaining signs but other symptoms had decreased significantly. However, these signs did not appear to be bothersome to the patients. Recent prospective studies regarding the natural course of TMJ internal derangement with irreducible disc displacement demonstrated that the symptoms showed annual improvement. Kurita et al reported that of 40 subjects, 75% showed a good course with spontaneous resolution of the clinical signs and symptoms, but 25% showed no change or worsening during a 2.5-year observation period.¹⁶ Sato et al also observed that TMJ tenderness and muscle tenderness had completely disappeared in all 21 untreated patients at a 27.1-month follow-up inspection.¹⁷ Therefore, the general conclusion is that, even in patients with untreated, symptomatic, temporomandibular disc displacement without reduction, symptoms generally improve over a long period of time, but the position of the disc does not generally change. Non-surgical treatment will improve symptoms other than clicking and crepitus. Chewing ability will not deteriorate significantly in the presence of joint noises. In this case series, although all patients could achieve normal mouth opening (MIO > 40 mm) and became free from tenderness, i.e. no TePs around the TMJ area on completion of treatment, there was little improvement in joint noises. Acupuncture thus seems to have little effect on improvement of joint noises, but appears to have a positive therapeutic effect on tenderness and pain around the TMJ, which is the chief complaint of most patients seeking therapy.

Rosted, on analysis of the choice of acupuncture points in the three positive randomised controlled trials of acupuncture for TMD, has recommended that ST6, ST7, SI18, GV20, GB20, BL10 can be used as local points on the face and neck. As a distal point, LI4 is recommended. After inserting the needles, they should be manipulated manually to achieve de qi sensation and left in-situ for 30 minutes. Treatment should be conducted every week for a total of six treatments, and continued once in

every three months until remission of the symptoms.¹⁸

In this case series, SI18 and GV20 were not chosen because, in general, they have not been found to be tender. Furthermore, it should be emphasised that all TePs in the TMJ, neck or upper back areas are treated concurrently. TE5 is added as an additional standard distal point. ST36 and LR3 have also been used in some cases. The use of TE5 and LR3 has not been reported in previous studies.^{2,4} The method and duration of needle manipulation is standardised. Needle retention was also 30 minutes. Thirty minutes may be the optimal length of stimulation for immediate release of endorphins. Prolonged stimulation appears to trigger release of cholecystokinin octapeptide (CCK-8), which is an opioid antagonist.¹⁹ Treatment was performed once a week, and 85% of patients in this series had resolution of tenderness around the TMJ after six visits. This concurs with Rosted's recommendations. However, unlike previous studies, additional point injection therapy was performed, after usual needling, to some residual tender points that remained after seven sessions. Reinforcement treatment was only given once (at the last visit), not every three months as recommended by Rosted. Instead, patients were advised to continue to wear their splint for one month, and to return for treatment if their symptoms recurred. Adverse effects were rare and minimal, supporting the fact that acupuncture is a very safe form of treatment.²⁰

An integrated approach, combining concepts of 'trigger point acupuncture' and TCA was used in the treatment regime. Such an approach is not new, and has been advocated by Seem.^{21,22} He has incorporated into one term the trigger points of Travell and Simons, the 'Ah shi' points of TCA, and the pressure points of Japanese acupuncture, and he refers to these collectively as 'tight tender points' (TTePs). Local point release of TTePs is through dry needling similar to trigger point needling, and needling of distal points is based on traditional meridian theory. The terminology of tender points (TePs) is used in the study because not every point encountered in the TMJ area exhibits 'tightness' or characteristics of trigger points. Strictly speaking, many of the TePs found are not myofascial trigger points as defined by

Travell and Simons because they are not found in the skeletal muscles. In this case series, diagnosis is purely based on a western approach, with emphasis on careful palpation of the affected area. Unlike the TCA approach, there is neither pulse and tongue diagnosis nor differentiation of syndromes for each individual patient. The 'trigger point acupuncture' approach for management of myofascial pain and dysfunction has been advocated by Travell and Simons and later by Baldry, although there is a similar, but not identical, concept of 'Ah shi points' in TCA.^{8:23-24} It has been suggested the location of myofascial trigger points correlates well with traditional acupuncture points.^{25:26} Acute trauma, such as lower third molar extraction, repetitive microtrauma as a result of faulty dental restorations, anxiety and depression, or improper body posture may all contribute to the pathogenesis of trigger points in the head and neck region. It has been established that referred pain to the TMJ, and other head and neck locations, is commonly the result of active myofascial trigger points in muscles of mastication, sternocleidomastoid, trapezius and even cervical muscles.²⁷ For example, ST5 and ST6 are associated with the masseter, while ST7 is associated with the lateral pterygoid. Myofascial trigger points in the lateral neck are principally found in sternocleidomastoid, while those in the upper back are mainly found in the trapezius, levator scapulae, supraspinatus and infraspinatus. Although some of the TePs in the TMJ area are not myofascial trigger points in a strict sense (e.g. TE17, TE21, SI19, GB2, etc.), they can be treated in a similar manner with dry needling. There are various ways of deactivating myofascial trigger points.²⁸ The neurophysiological effects of needling of myofascial trigger points are currently being explored. Relaxation of 'stuck' myofibrils, increased local blood supply, the release of spinal dynorphin and enkephalin have all been postulated to explain the rehabilitative effects of trigger point needling. Deeply applied techniques in the form of acupuncture dry needling and point injections were employed in this case series.

ST6 is a trigger point in the masseter muscle. Its location is approximately one fingerbreadth anterior and superior to the angle of the jaw at the prominence of the muscle. Needling technique is

either perpendicular insertion or slightly oblique towards ST7. The usual depth is 10 to 15mm to get 'de qi' sensation. ST7 is located at the lower border of the zygomatic arch, in the depression anterior to the condyloid process of the mandible, which corresponds to the sigmoid notch. In the depth of the notch, the needle reaches the lateral pterygoid muscle. The needling technique used is either perpendicular or slightly oblique - about 20 to 30 degrees upwards through the sigmoid notch until 'de qi' sensation is felt. The usual depth of penetration is 15 to 20 mm. The needle will reach either the inferior or superior division of the lateral pterygoid muscle in this way. The pre-tragal points (TE21, SI19, GB2) are needled when the mouth is slightly opened. They lie in front of the tragus but behind the condylar process of the mandible. Insertion is perpendicular, and should avoid pointing posteriorly in order not to puncture through the external auditory meatus. Also, these three points lie over the temporal artery and the auriculotemporal nerve, which are susceptible to injury, especially if the points are needled obliquely in a caudal or cranial direction. The usual depth is 15 to 20 mm and should correspond to the connective tissues between the external auditory meatus and the condyloid process of the mandible. The exact anatomical correspondence of *Qian Zheng* was not described in most of the acupuncture textbooks. However, Low described it as being in the masseter muscle associated with the buccal branch of the facial nerve.²⁹ This point has been used in China, together with TE17, for Bell's palsy. Insertion is either perpendicular or obliquely forward to a depth of 15 to 20mm. Knowledge of anatomy, and the skill to apply it, is arguably the most important facet of safe and competent acupuncture practice. Interested readers should refer to a recent excellent review of the relevant anatomy of acupuncture points in the head and neck region by Peuker and Cummings.³⁰

In this case series, 85% of patients in each group were rendered free of TePs around the TMJ after six visits. There seems no significant difference whether patients have electroacupuncture or not. However, this should not be taken too seriously because the sample of the manual group is small and it is difficult to make a meaningful comparison between the two groups. Most

experimental work shows greater effects with EA. Furthermore, it has been shown that low frequency (2Hz) and high frequency (100Hz) EA induces the release of different neuromodulators such as β -endorphin, met-enkephalin, dynorphins and serotonin in both experimental animals and humans. One could thus anticipate that if low frequency stimulation occurs alternately with high frequency stimulation, both enkephalins and dynorphins will be released successively or simultaneously to produce a more potent analgesic effect via a synergistic interaction between the opioid peptides.¹⁹ However, in this case series, a dense-dispersed mode was not chosen. Instead, a continuous wave of 40Hz frequency was chosen because the first few patients treated with EA felt most comfortable with this. Better results might be obtained in the EA group with a dense-dispersed mode, and this could be the subject of future research on TMD treated with EA. Compared with manual acupuncture, there are other advantages of electroacupuncture. It is less tiring for the operator as it can replace long time-sustained manual manipulation of the needles and the amount of stimulation can be uniformly controlled.

With respect to point injection, a mixture of corticosteroid and local anaesthetic, which has been shown to give better results than local anaesthetic alone, was used.³¹ However, a recent systematic review by Cummings and White does not support this notion.³² The principal findings of the review were that, when treating myofascial trigger point pain with trigger point injection, the nature of the injected substance makes no difference to the outcome, and that wet needling is not therapeutically superior to dry needling. It is not possible to assess the effectiveness of point injection therapy in this case series, and it is possible that continued treatment with dry needling alone would have been as effective. This is supported by the fact that two patients, who refused point injection therapy, had their residual tender points effectively treated with a further five sessions of acupuncture. However, it is possible that the same effect is achieved more quickly with injection therapy in resistant cases.

The 0.8% incidence of fainting, although calculated from a very small sample of 370 treatments, may be regarded as high, and not

acceptable by many acupuncturists. Chen et al reported a 0.19% incidence of syncope among 28,285 acupuncture procedures.³³ They found that patients who experienced syncope were all in a seated or upright posture when they received acupuncture. Others reported an even lower figure (Odsberg et al 0.02%; White et al 0.02%; and Ernst et al 0.1%).³⁴⁻³⁶ A recent systematic review of prospective studies of the safety of acupuncture by Ernst and White concluded that feelings of faintness and syncope were uncommon in association with acupuncture, with an incidence of 0% to 0.3%.³⁷ In this case series, the three episodes of fainting all happened within 30 seconds of needle insertion at distal points (two after insertion at LI4 and one after insertion at TE5). All the patients recovered uneventfully soon after all the needles were removed and the patient was laid supine on the dental chair. Perhaps there are ways to reduce this figure, as this is theoretically an avoidable adverse effect of treatment. Patients could be treated fully supine initially, and distal points could be needled first. Use of needles of a smaller gauge could also be considered to reduce needling pain during insertion.

The National Institute of Health (NIH) recommendation for management of TMD in 1996 concluded that universally accepted scientifically based guidelines for diagnosing and managing TMD are not available, and a conservative approach to treatment is recommended for the vast majority of patients.³⁸ There are a variety of conservative treatment modalities such as splint therapy, medication (NSAIDs, muscle relaxants, tricyclic antidepressants), physical therapy (superficial heat, ultrasound), and others such as counselling, biofeedback, jaw exercise, relaxation techniques, acupuncture, etc.³⁹⁻⁴¹ Each modality has its own proponents and literature support for effectiveness, but good quality randomised controlled trials (RCTs) are few.⁴² Madland et al, in reviewing the evidence base for orofacial pain and TMD, has concluded that to distinguish between joint disorders and muscle disorders is important for TMD management.⁴³ They also comment that the benefit of anti-inflammatory painkillers has not been clinically investigated. They suggest that the mode of actions of different treatment regimes may be through non-specific effects.

Previous studies using acupuncture in TMD have used occlusal splint therapy as controls.^{2,4} In this series, occlusal splint in the form of a soft mouthguard was prescribed on the second visit for use during sleep. This form of mouthguard, unlike those anterior repositioning splints, is a non-invasive and reversible form of treatment. It is more comfortable to wear the soft splints than those made of hard acrylics. Splints may have a role to play by maintaining a degree of stretch in the muscles of mastication.

In this case series, instantaneous improvement is likely to be due to a specific effect of the acupuncture treatment rather than a placebo effect, since before treatment 87% of patients had received NSAIDs without noticeable improvement, and 55% of them had had pain for over three months. After the first visit for acupuncture treatment, 84% of patients reported improvement and only 15% of patients received another NSAID. Tricyclic antidepressants or benzodiazepines are also poorly tolerated by patients because of their side effects such as drowsiness and xerostomia. In this case series acupuncture has been well received by patients, and most managed to complete the whole course of treatment until their pain subsided.

The effectiveness of acupuncture may be attributed to the following factors:

1. acupuncture analgesia induced through its segmental and heterosegmental effects;^{19,44}
2. increase in circulation in the areas concerned, hastening a healing response in the tissues; and
3. release of trigger points.

Conclusion

The results of this case series indicate that most patients with TMD became symptom free within six sessions of the regime described. Complications were rare and minor. Acupuncture treatment, in combination with splint therapy and point injection therapy, is effective for management of TMD. However, further research, preferably in the form of randomised controlled trials, should be conducted to ascertain its effectiveness over other treatment modalities.

Reference List

1. Gray RJ, Davies SJ, Quayle AA. A clinical approach to temporomandibular disorders. 1. Classification and functional anatomy. *Br Dent J* 1994;176(11):429-35.
2. Raustia AM, Pohjola RT, Virtanen KK. Acupuncture compared with stomatognathic treatment for TMJ dysfunction. Part I: A randomised study. *J Prosthet Dent* 1985;54(4):581-5.
3. Johansson A, Wenneberg B, Wagersten C, Haraldson T. Acupuncture in treatment of facial muscular pain. *Acta Odontol Scand* 1991;49(3):153-8.
4. List T, Helkimo M, Andersson S, Carlsson GE. Acupuncture and occlusal splint therapy in the treatment of craniomandibular disorders. Part I. A comparative study. *Swed Dent J* 1992;16(4):125-41.
5. Merchant N. Facial pain: A review of 200 cases treated with acupuncture. *Acupunct Med* 1995;13(2):110-1.
6. Ernst E, White A. Acupuncture as a treatment for temporomandibular joint dysfunction: a systematic review of randomised trials. *Arch Otolaryngol Head Neck Surg* 1999;125(3):269-72.
7. World Health Organisation. *Acupuncture: Review and Analysis of Reports on controlled clinical trials*. Geneva: WHO; 2002. p. 9.
8. Travell JG, Simons DG. *Myofascial Pain and Dysfunction. The Trigger Point Manual. Volume 1. The Upper Half of the Body*. 1st ed. Baltimore: Williams and Wilkins; 1983.
9. Alvarez DJ, Rockwell PG. Trigger Points: diagnosis and management. *Am Fam Physician* 2002;65(4):653-60.
10. Deadman P, Al-Khafaji M, Baker K. *A Manual of Acupuncture*. Hove: Journal of Chinese Medicine; 2001. p.105.
11. Mann F. The Liver or upper digestive dysfunction. In: *Reinventing Acupuncture: A New Concept of Ancient Medicine*. Oxford: Butterworth-Heinemann; 2000. p. 59-74.
12. Campbell A. Generalised Stimulation. In: *Acupuncture in Practice: Beyond Points and Meridians*. Butterworth-Heinemann, Oxford; 2001. p. 132-7.
13. Okeson JP, Hayes DK. Long-term results of treatment for temporomandibular disorders: an evaluation by patients. *J Am Dent Assoc* 1986;112(4):473-8.
14. de Leeuw R, Boering G, Stegenga B, de Bont LG. Clinical signs of TMJ osteoarthritis and internal derangement 30 years after nonsurgical treatment. *J Orofac Pain* 1994;8(1):18-24.
15. de Leeuw R, Boering G, Stegenga B, de Bont LG. Symptoms of temporomandibular joint osteoarthritis and internal derangement 30 years after non-surgical treatment. *Cranio* 1995;13(2):81-8.
16. Kurita K, Westesson PL, Yuasa H, Toyama M, Machida J, Ogi N. Natural course of untreated symptomatic temporomandibular joint disc displacement without reduction. *J Dent Res* 1998;77(2):361-5.
17. Sato S, Sakamoto M, Kawamura H, Motegi K. Long-term changes in clinical signs and symptoms and disc position and morphology in patients with nonreducing disc displacement in the temporomandibular joint. *J Oral Maxillofac Surg* 1999;57(1):23-9.
18. Rosted P. Practical recommendations for the use of acupuncture in the treatment of temporomandibular disorders based on the outcome of published controlled studies. *Oral Dis* 2001;7(2):109-15.

19. Ulett GA, Han S. *The Biology of Acupuncture*. St Louis: Warren H Green; 2002. p. 39-66.
20. Vincent C. The safety of acupuncture. *BMJ* 2001; 323(7311):467-8.
21. Seem MD. *A New American Acupuncture: Acupuncture Osteopathy - The Myofascial Release of the Bodymind's Holding Patterns*. Boulder: Blue Poppy Press; 1993.
22. Seem MD. *Acupuncture Physical Medicine: An Acupuncture Touchpoint Approach to the Treatment of Chronic Fatigue, Pain and Stress Disorders*. Boulder: Blue Poppy Press; 2000.
23. Travell JG, Simons DG. *Myofascial Pain and Dysfunction. The Trigger Point Manual. Volume 2. The Lower Extremities*. Baltimore: Williams and Wilkins; 1992.
24. Baldry PE. *Acupuncture, Trigger Points and Musculoskeletal Pain*. 2nd ed. Churchill Livingstone, Edinburgh; 1993.
25. Melzack R, Stillwell DM, Fox EJ. Trigger points and acupuncture points for pain: correlations and implications. *Pain* 1977;3(1):3-23.
26. Hong CZ. Myofascial trigger points: pathophysiology and correlation with acupuncture points. *Acupunct Med* 2000; 18(1):41-7.
27. Sessle BJ. The neurobiology of facial and dental pain: present knowledge, future directions. *J Dent Res* 1987; 66(5):962-81.
28. Baldry PE. Management of myofascial trigger point pain. *Acupunct Med* 2002;20(1):2-10.
29. Low R. *The Non-Meridian Points of Acupuncture*. Wellingborough: Thorsons (HarperCollins); 1988. p. 12.
30. Peuker E, Cummings M. Anatomy for the acupuncturist – facts & fiction. 1: The head and neck region. *Acupunct Med* 2003;21(1-2):2-8.
31. Bourne IH. Treatment of chronic back pain. Comparing corticosteroid-lignocaine injections with lignocaine alone. *Practitioner* 1984;228(1389):333-8.
32. Cummings TM, White AR. Needling therapies in the management of myofascial trigger point pain: a systematic review. *Arch Phys Med Rehabil* 2001;82(7):986-92.
33. Chen FP, Hwang SJ, Lee HP, Yang HY, Chung C. Clinical study of syncope during acupuncture treatment. *Acupunct Electrother Res* 1990;15(2):107-19.
34. Odsberg A, Schill U, Haker E. Acupuncture treatment: side effects and complications reported by Swedish physiotherapists. *Complement Ther Med* 2001;9(1):17-20.
35. White A, Hayhoe S, Hart A, Ernst E; BMAS and AACP. British Medical Acupuncture Society and Acupuncture Association of Chartered Physiotherapists. Survey of adverse events following acupuncture (SAFA): a prospective study of 32,000 consultations. *Acupunct Med* 2001;19(2):84-92.
36. Ernst G, Strzyz H, Hagmeister H. Incidence of adverse effects during acupuncture therapy—a multicentre survey. *Complement Ther Med* 2003;11(2):93-7.
37. Ernst E, White AR. Prospective studies of the safety of acupuncture: a systematic review. *Am J Med* 2001; 110(6):481-5.
38. National Institutes of Health Technology Assessment Conference Statement. Management of temporomandibular disorders. *J Am Dent Assoc* 1996;127(11):1595-606.
39. Harris M, Feinmann C, Wise M, Treasure F. Temporomandibular joint and orofacial pain: clinical and medicolegal management problems. *Br Dent J* 1993;174(4):129-36.
40. Foreman PA. The changing focus of chronic temporomandibular disorders: management within a hospital-based, multidisciplinary pain centre. *N Z Dent J* 1998;94(415):23-31.
41. Foreman PA. Temporomandibular joint and myofascial pain dysfunction: some current concepts. Part 1: diagnosis. Part 2: treatment. *N Z Dent J* 1985;81(364):47-57.
42. Rosted P. The use of acupuncture in dentistry: a review of the scientific validity of published papers. *Oral Dis* 1998;4(2):100-4.
43. Madland G, Newton-John T, Feinmann C. Chronic idiopathic orofacial pain: I. What is the evidence base? *Br Dent J* 2001;191(1):22-4.
44. Filshie J, White A. *Medical Acupuncture: A Western Scientific Approach*. Edinburgh: Churchill Livingstone; 1998.



A case series of temporomandibular disorders treated with acupuncture, occlusal splint and point injection therapy

Yiu-kai Wong and Jason Cheng

Acupunct Med 2003 21: 138-149

doi: 10.1136/aim.21.4.138

Updated information and services can be found at:

<http://aim.bmj.com/content/21/4/138>

Email alerting service

These include:

Receive free email alerts when new articles cite this article. Sign up in the box at the top right corner of the online article.

Notes

To request permissions go to:

<http://group.bmj.com/group/rights-licensing/permissions>

To order reprints go to:

<http://journals.bmj.com/cgi/reprintform>

To subscribe to BMJ go to:

<http://group.bmj.com/subscribe/>